

## **Catheter Ablation for Brugada Syndrome**

Author: Dingxin Qin MD\*, Weeranun D. Bode MD\*, E. Kevin Heist MD PhD\*, PhD, Steven A. Lubitz MD, MPH\*, Pasquale Santangeli MD<sup>#</sup>, Jeremy Ruskin MD\*, and Moussa Mansour MD\*.

\* Cardiac Arrhythmia Unit, Heart Center, Massachusetts General Hospital, Boston, MA, USA

<sup>#</sup> Division of Cardiology, Electrophysiology Section, Hospital of the University of Pennsylvania, Philadelphia, Pennsylvania

Address for correspondence:

Moussa Mansour, MD

Cardiac Arrhythmia Service, Massachusetts General Hospital

GRB 815

55 Fruit Street, Boston, MA, 02114

Email: [mmansour@partners.org](mailto:mmansour@partners.org)

Financial Disclosures:

DQ: None

WB: None

EKH: Consulting: (Abbott, Boston Scientific, Medtronic, Pfizer), Research grants: (Abbott, Biotronik, Pfizer), Honorarium (Medtronic, Biotronik, Abbott)

SAL: Dr. Lubitz is supported by NIH grant 1R01HL139731 and American Heart Association 18SFRN34250007. Dr. Lubitz receives sponsored research support from Bristol Myers Squibb / Pfizer, Bayer AG, Boehringer Ingelheim, and Fitbit, and has consulted for Bristol Myers Squibb / Pfizer and Bayer AG.

JR: Dr. Ruskin has served as a consultant for Acesion Pharma, Advanced Medical Education, Correio, Hanover Medical, InCarda, Janssen, LuxCath, Medtronic, Novartis, and Pfizer; and has an equity interest in Ablacor, Celero Systems, Element Science, Gilead, Infobionic, NewPace, and Portola.

MM: Dr. Mansour has served as a consultant for Biosense Webster, Abbott, Medtronic, Boston Scientific, Janssen, Philips, Novartis, Baylis, and SentreHeart; has received research grants from Biosense Webster, Abbott, Boston Scientific, Medtronic, Pfizer, Boehringer Ingelheim; and has an equity interest in EPD Solutions, NewPace Ltd., and Affera.

**Abstract:**

We report a case of catheter ablation of Brugada syndrome (BrS) in a patient with refractory ventricular fibrillation (VF) despite quinidine therapy. We performed epicardial substrate mapping which identified an area of abnormal fractionated, prolonged electrogram in the anterior right ventricular outflow tract. Warm saline infusion into the pericardial space induced further delay of the local electrogram, consistent with BrS physiology. Coronary angiogram confirmed the area was distant from major coronary arteries. Ablation was performed in this area which eliminated local abnormal electrograms and led to disappearance of coved-type ST elevation in V1-V2. No VF recurred at 3-month follow-up.

**Introduction:**

Previous studies have shown that Brugada syndrome (BrS) is associated with interstitial fibrosis and reduced gap junction expression in the epicardial right ventricular outflow tract (RVOT) <sup>1</sup>. There is emerging evidence that epicardial substrate modification in the RVOT by catheter ablation could be an effective treatment for symptomatic drug refractory BrS <sup>2</sup>. However, the data regarding this topic is limited.

This report discusses the case of catheter ablation for Brugada syndrome in a patient with recurrent polymorphic ventricular tachycardia and ventricular fibrillation (PMVT/VF) despite pharmacological therapy.

**Case Report:**

A 55-year-old woman, with a history of BrS and subcutaneous implantable cardioverter-defibrillator (ICD) on quinidine, was admitted for recurrent episodes out-of-hospital PMVT/VF and ICD shocks. Device interrogation showed 3 sequential episodes of PMVT/VF within 15 minutes that triggered 6 ICD shocks in total, including one episode that persisted through 4 ICD shocks before its spontaneous termination. Due to the severity of the events despite quinidine therapy, the patient was taken for catheter ablation. Quinidine was held for 5 days prior to the ablation.

The procedure was performed under general anesthesia. The pericardial space was accessed anteriorly using a micro-puncture apparatus, which was subsequently exchanged with for a deflectable sheath (Agilis, Abbott, Saint Paul, MN). A linear multipolar mapping catheter

(DECANAV<sup>®</sup>, Biosense Webster, Irvine, CA) was used to map the epicardial surface. Voltage and sinus activation maps (Figure 1) were obtained (CARTO<sup>®</sup>3, Biosense Webster, Irvine, CA). Areas of delayed, fractionated, and prolonged potentials were annotated on the epicardial substrate map, and these were concentrated over the RVOT. Intracardiac echo was also used to reconstruct a 3D shell of the endocardium of both ventricles (CARTOSOUND<sup>®</sup>, Biosense Webster, Irvine, CA). The epicardial and endocardial maps were then integrated with a 3D CT image of the aortic root and coronary arteries (Figure 2). After the location and timing of the areas of delayed activation were identified, 60 mL of warm water (102F) was injected into the epicardial space. This resulted in further delay of the abnormal electrical activity in the RVOT, consistent with BrS pathophysiology (Figure 2A and 2B). A left and right coronary angiogram was then performed to ensure a safe distance between the targeted area in epicardial RVOT and the proximal coronary arteries. Ablation targeted the fractionated potentials with delayed activation timing beyond the end of the QRS (Figure 3), using radiofrequency energy up to 40W (STSF, Biosense Webster, Irvine, CA). After ablation, epicardial voltage and activation maps were acquired and demonstrated the elimination of the late abnormal local electrical activity (Figure 3). No premature ventricular contractions were seen during the procedure. Post-procedure EKG showed disappearance of the coved-type ST elevation in V1-V2 (Figure 3). The patient recovered well and had no further PMVT/VF episodes since the procedure three months ago.

## **Discussion**

This case illustrates an example of successful epicardial RVOT substrate modification in a patient with BrS. It highlights the important fact that, at least in a subset of cases, the



pathological substrate in this disease is not a diffuse process, rather it is localized to a relatively small area in the epicardial RVOT.

BrS is a condition associated with structural alterations and electrical remodeling in the epicardial RVOT area<sup>1, 3-4</sup>. Attempts at modifying the abnormal substrate in the epicardial RVOT with catheter ablation have been previously reported (Table 1)<sup>2, 5-9</sup>. Other ablation strategies, including endocardial ablation of VF-triggering PVC ablation<sup>2</sup> in combination with epicardial ablation, have also have been described , but the success of the procedure appears to be driven mostly by epicardial ablation. The abnormal intracardiac electrical activity in BrS can be subtle and probably dynamic. Revealing the epicardial substrate and provoking the BrS phenotype is an important part of the ablation. This can be performed by the infusion of sodium channel blockers. In patients with high VF burden where the infusion of these medications can precipitate an arrhythmia storm, intra-pericardial warm saline can be used and that has a transient effect.

The end points of the procedure represent another important consideration. Elimination of the local delayed electrical activity is generally feasible because the targeted area tends to be relatively small and reasonably far from the coronary arteries in most patients. Another end point is the elimination of the BrS pattern on the surface 12-lead ECG. This is an important end point, and persistence of the BrS after ablation has been associated with VT/VF recurrence, while its disappearance was predictive of good clinical outcomes <sup>2, 5-8</sup>. However, it is important to keep in mind that elimination of the BrS ECG pattern may not be obvious immediately after the procedure because the ECG can be affected by inflammation and pericarditis that can present

as ST segment abnormalities, and the normalization may take weeks to become obvious. The inducibility of VT/VF post-ablation as an end point remain controversial <sup>2</sup>.

## **Conclusion**

Successful catheter ablation for BrS can be achieved by targeting the abnormal substrate in the epicardial anterior RVOT. Multicenter studies are needed to compare different mapping and ablation strategies, define the endpoint of catheter ablation, and confirm the effectiveness of this approach.

## **References:**

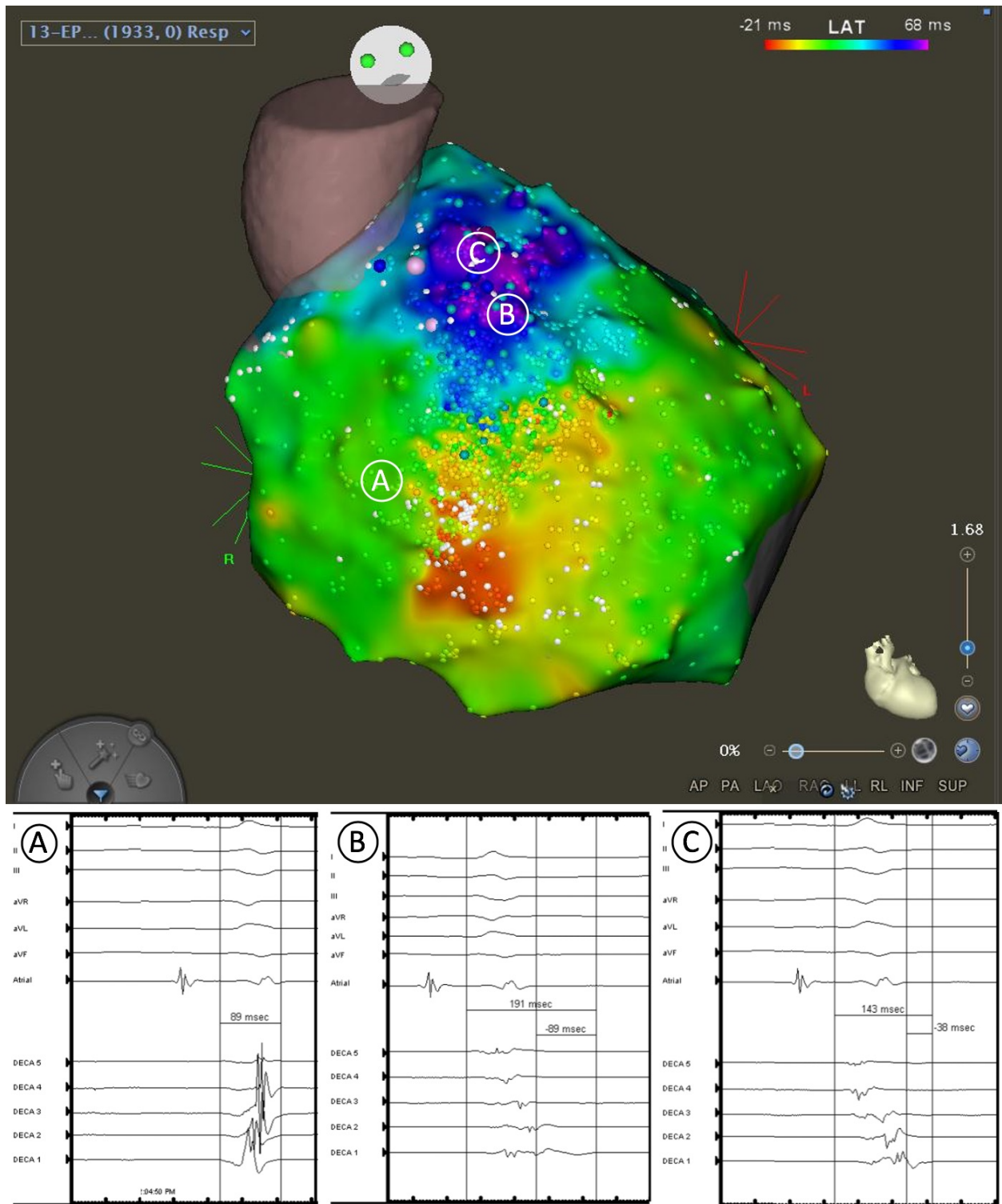
1. Nademanee K, Raju H, de Noronha SV, et al. Fibrosis, Connexin-43, and Conduction Abnormalities in the Brugada Syndrome. *Journal of the American College of Cardiology*. 2015;66(18):1976-1986. doi:10.1016/j.jacc.2015.08.862
2. Fernandes GC, Fernandes A, Cardoso R, et al. Ablation strategies for the management of symptomatic Brugada syndrome: A systematic review. *Heart Rhythm*. 2018;15(8):1140-1147. doi:10.1016/j.hrthm.2018.03.019
3. Takagi M, Aihara N, Kuribayashi S, et al. Localized right ventricular morphological abnormalities detected by electron-beam computed tomography represent arrhythmogenic substrates in patients with the Brugada syndrome. *Eur Heart J*. 2001;22(12):1032-1041. doi:10.1053/euhj.2000.2424
4. Nagase S, Kusano KF, Morita H, et al. Epicardial electrogram of the right ventricular outflow tract in patients with the Brugada syndrome: using the epicardial lead. *J Am Coll Cardiol*. 2002;39(12):1992-1995. doi:10.1016/s0735-1097(02)01888-0
5. Nademanee K, Veerakul G, Chandanamattha P, et al. Prevention of ventricular fibrillation episodes in Brugada syndrome by catheter ablation over the anterior right ventricular outflow tract epicardium. *Circulation*. 2011;123(12):1270-1279. doi:10.1161/CIRCULATIONAHA.110.972612
6. Brugada J, Pappone C, Berruezo A, et al. Brugada Syndrome Phenotype Elimination by Epicardial Substrate Ablation. *Circ Arrhythm Electrophysiol*. 2015;8(6):1373-1381. doi:10.1161/CIRCEP.115.003220
7. Zhang P, Tung R, Zhang Z, et al. Characterization of the epicardial substrate for catheter ablation of Brugada syndrome. *Heart Rhythm*. 2016;13(11):2151-2158. doi:10.1016/j.hrthm.2016.07.025
8. Chung F-P, Raharjo SB, Lin Y-J, et al. A novel method to enhance phenotype, epicardial functional substrates, and ventricular tachyarrhythmias in Brugada syndrome. *Heart Rhythm*. 2017;14(4):508-517. doi:10.1016/j.hrthm.2017.01.006
9. Pappone C, Brugada J, Vicedomini G, et al. Electrical Substrate Elimination in 135 Consecutive Patients With Brugada Syndrome. *Circ Arrhythm Electrophysiol*. 2017;10(5):e005053. doi:10.1161/CIRCEP.117.005053

**Figure Legend:**

**Figure 1.** Epicardial activation mapping of the right ventricle. Normal RV electrogram (A) and abnormal electrogram in the RVOT area (B, C) are shown. Normal electrogram duration (A) was measured from the beginning of the QRS complex. Abnormal electrogram duration (B, C), which extended beyond the end of the QRS complex, was measured from both the beginning and the end of the QRS complex.

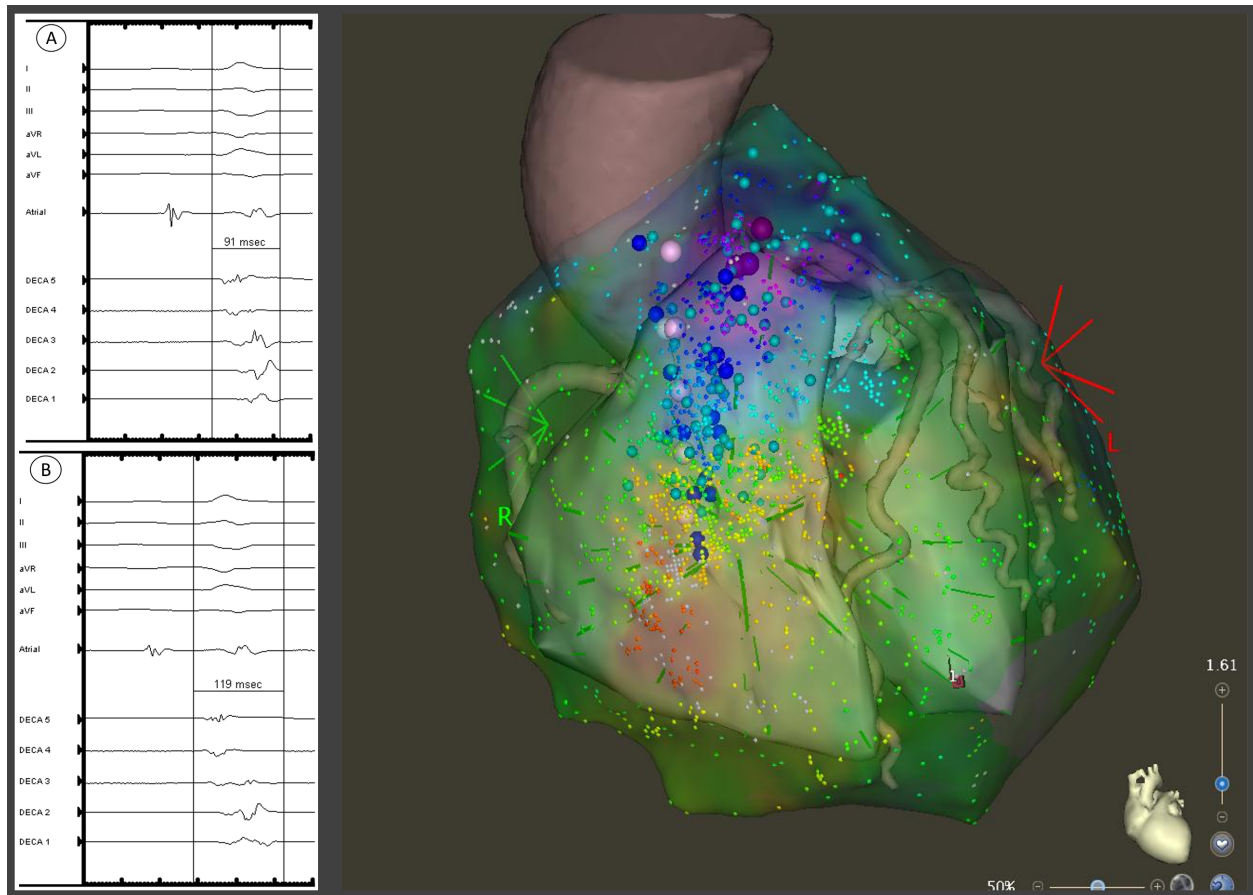
**Figure 2.** Integration of epicardial activation map with CARTOSOUND image and 3D CT scan with RVOT electrograms before (A) and after (B) pericardial warm saline infusion. The electrogram became more delayed and fractionated after warm saline infusion. The duration of the electrogram was measured from the beginning of the QRS complex.

**Figure 3.** Epicardial activation map post-ablation. Ablation lesions are shown. The fractionated delayed electrograms in the RVOT area were eliminated. Compared with pre-ablation EKG (A), post-ablation EKG (B) showed disappearance of the coved-type ST elevation in V1-V2.

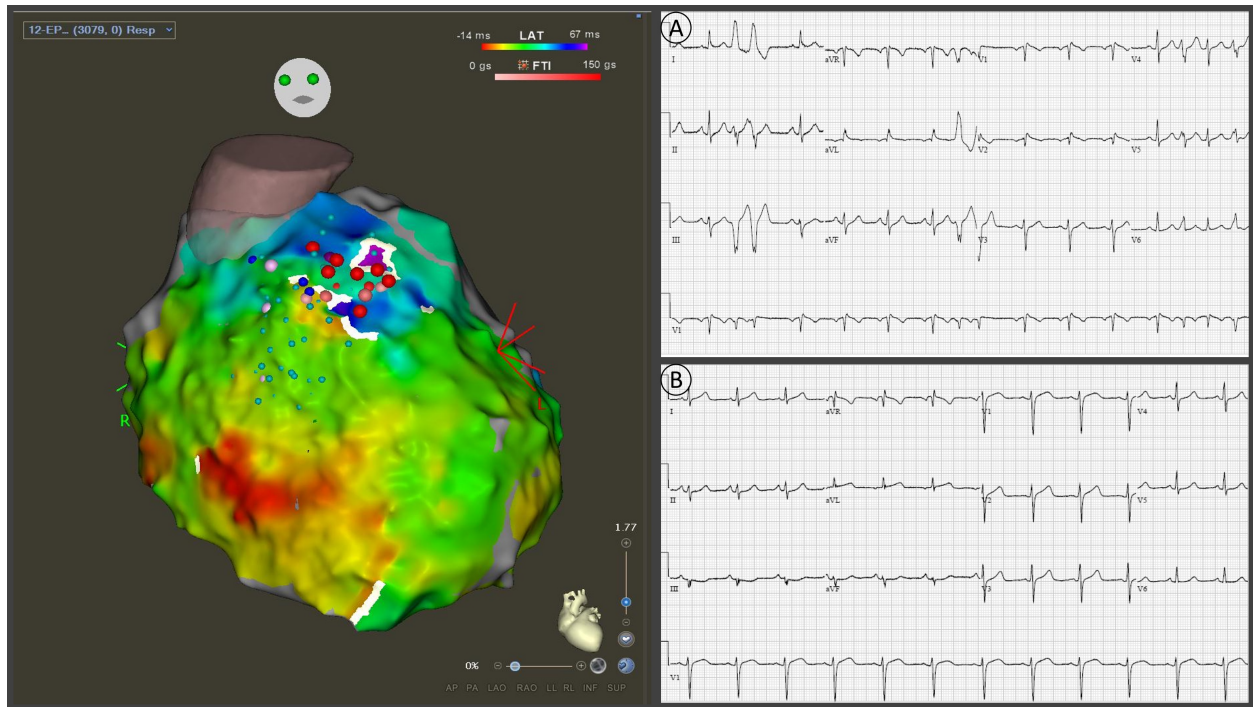


**Figure 1.** Epicardial activation mapping of the right ventricle. Normal RV electrogram (A) and abnormal electrogram in the RVOT area (B, C) are shown. Normal electrogram duration (A)

was measured from the beginning of the QRS complex. Abnormal electrogram duration (B, C), which extended beyond the end of the QRS complex, was measured from both the beginning and the end of the QRS complex.



**Figure 2.** Integration of epicardial activation map with CARTOSOUND image and 3D CT scan with RVOT electrograms before (A) and after (B) pericardial warm saline infusion. The electrogram became more delayed and fractionated after warm saline infusion. The duration of the electrogram was measured from the beginning of the QRS complex.



**Figure 3.** Epicardial activation map post-ablation. Ablation lesions are shown. The fractionated delayed electrograms in the RVOT area were eliminated. Compared with pre-ablation EKG (A), post-ablation EKG (B) showed disappearance of the coved-type ST elevation in V1-V2.



**Table 1.** Case series of epicardial +/- endocardial mapping and catheter ablation for BrS

	N	Mapping	Ablation Site	Provocation Agent	VT/VF pre-ablation	VT/VF Free post-ablation	Adverse Events
Nademanee 2011 <sup>5</sup>	9	Epi + Endo substrate	Epi RVOT	Ajmaline	9 (100%)	8 (89%)	2 pericarditis
Brugada 2015 <sup>6</sup>	14	Epi +/- Endo substrate	Epi RV and RVOT	Flecainide	14 (100%)	14 (100%)	1 pericarditis
Zhang 2016 <sup>7</sup>	11	Epi + Endo substrate	Epi RVOT	Propafenone or procainamide	11 (100%)	8 (73%)	2 pericarditis
Chung 2017 <sup>8</sup>	15	Epi + Endo substrate + PVC	Epi RVOT and PVC	Epicardial warm water	15 (100%)	14 (93%)	-
Pappone 2017 <sup>9</sup>	135	Epi + Endo substrate	Epi RV and RVOT	Ajmaline	135 (100%)	133 (98.5%)	5 pericardial effusion