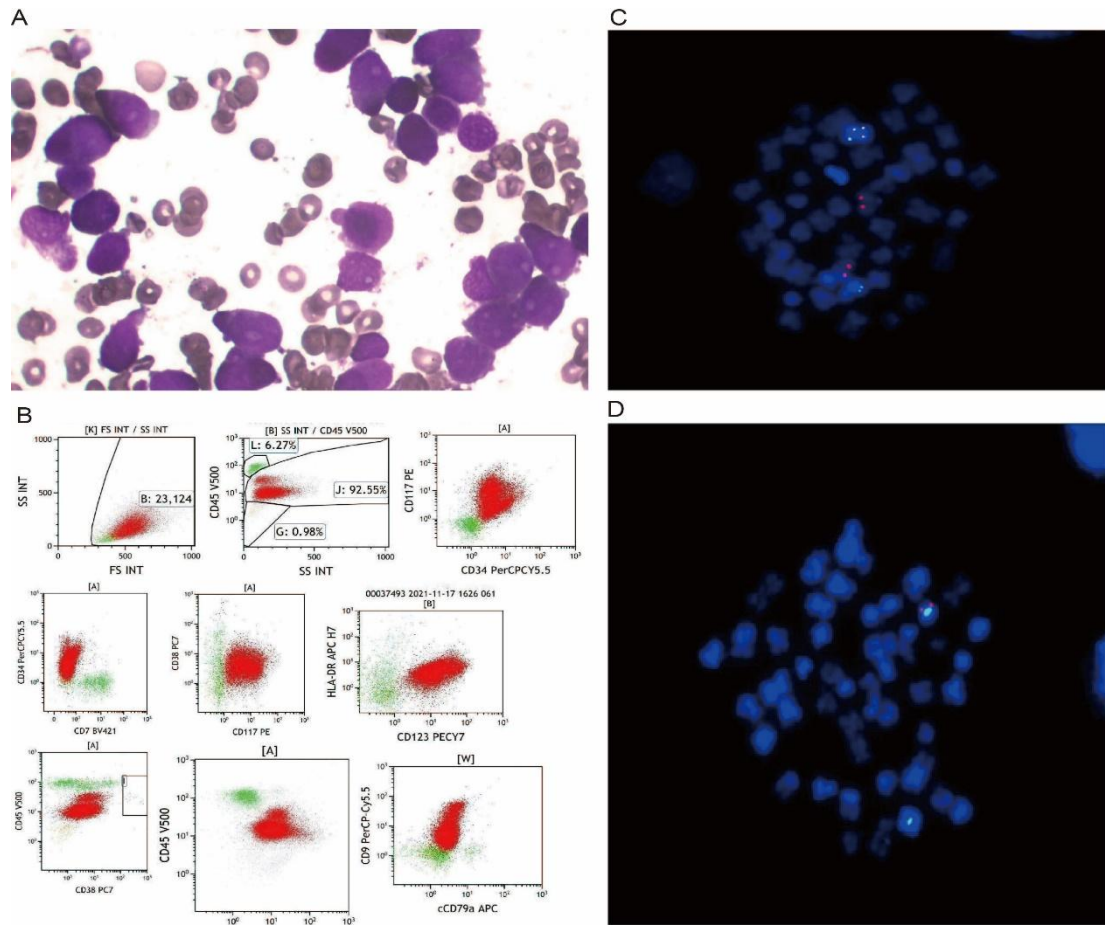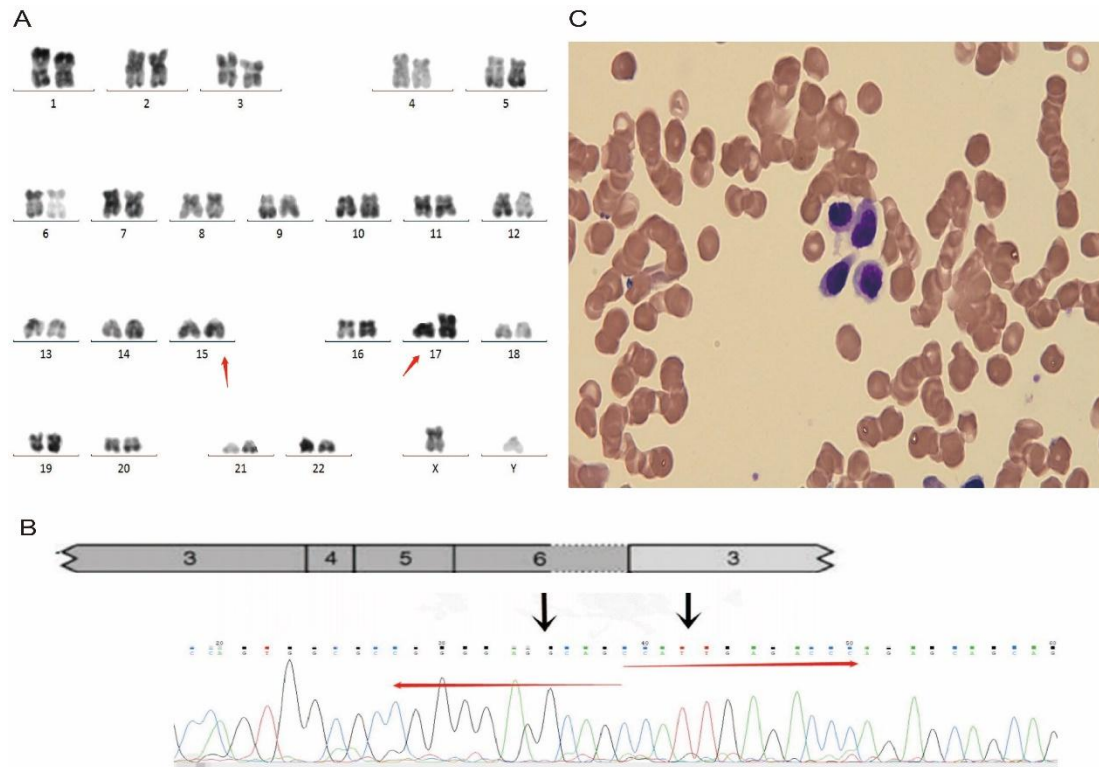
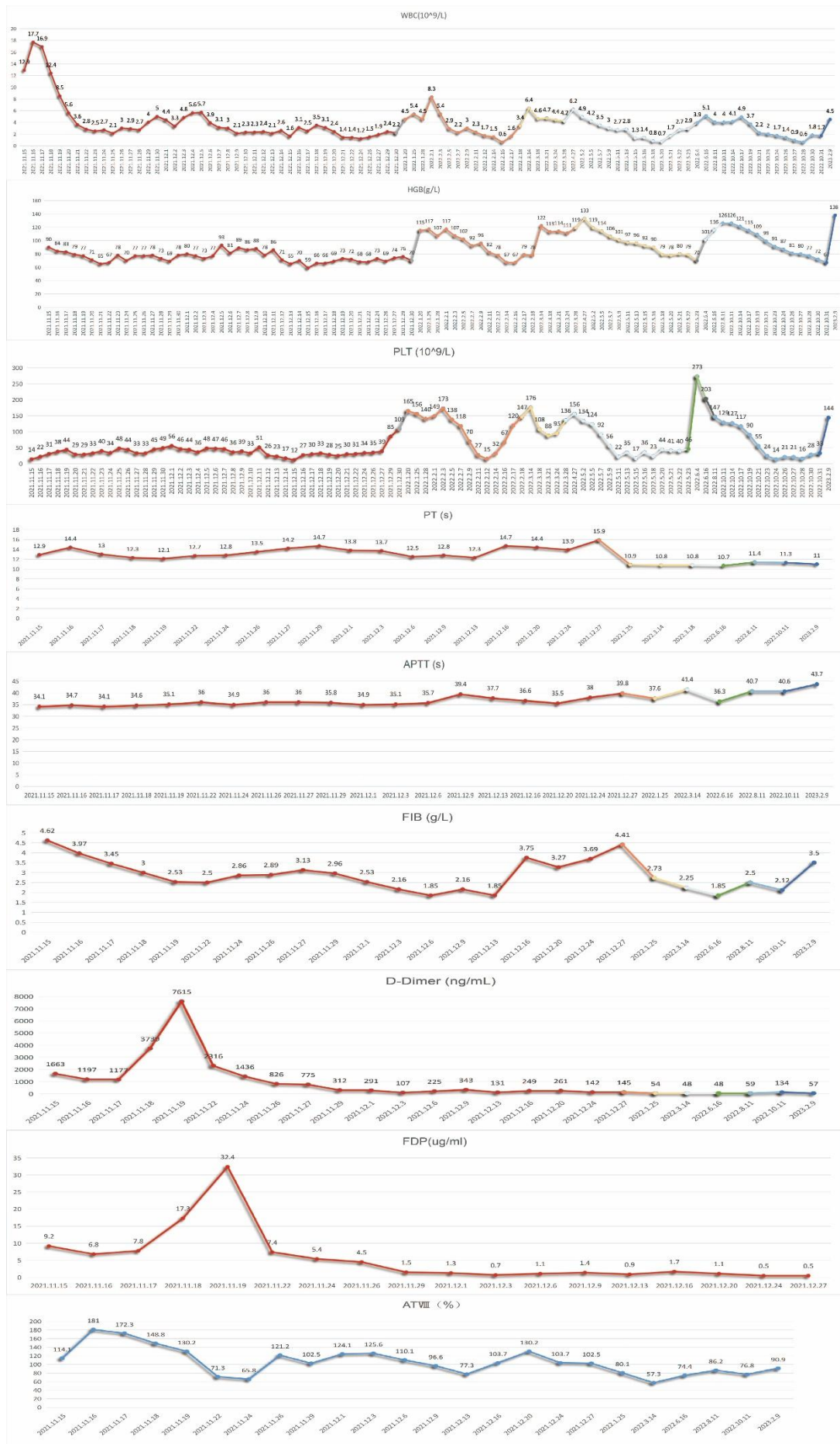


**Fig. 1** Morphology, immunophenotyping and FISH. (A) Bone marrow morphology upon initial diagnosis. The bone marrow aspirate shows hypercellular marrow with increased abnormal promyelocytes, which had a visible round or oval, distorted, folded nucleus. (B) Leukemia cells expressed MPO, CD13, CD33 CD99, CD117, CD123, but do not express CD2, CD7, CD19, CD21, CD34, HLA-DR, TDT. (C) FISH study using a PML-RARA dual-color, dual-fusion translocation probe. (D) The TP53 (17P13) gene is labelled red with a two-color TP53 probe, indicating a positive TP53 gene deletion.



**Fig.2** Karyotyping, sequencing analysis and morphology. (A) The karyotyping of 46 XY, ider(q10) ins (q21; q24)/46, XY. The arrows indicate abnormal chromosomes. (B) Diagrammatic representation and sequencing information of PML-RARA fusion transcripts of the patient. (C) Bone marrow morphology after treatment shows morphological and cytogenetic remission.



**Fig. 3** The trend of laboratory examination during treatment.